

Respiration Anatomy - Muscles of Respiration

see muscle atlas pictures 50, 82-3, 85, 87, 89, 93, 98-9, 105-6; also see coloring book (pages 48, 50, 51, 54, and 56)

Major ideas: major and accessory thoracic muscles of inspiration, accessory muscles of expiration

Muscle key:

(a) = know origin, insertion, action, and be able to identify

(b) = know action and be able to identify; given one of the attachments (origin or insertion), be able to name the other

also see the study guide for midterm 1

MUSCLES OF INSPIRATION

Major muscle of inspiration: Diaphragm _(a)

central tendon

landmarks/openings:

- foramen vena cava
- aortic hiatus
- esophageal hiatus

places of attachment:

origins (3):

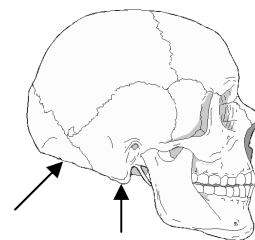
insertion:

major vs. accessory muscles:

Accessory Thoracic Muscles of Inspiration

| <u>Name</u> | <u>Origin</u> | <u>Insertion</u> | <u>Action</u> |
|---|--|--------------------------------------|---------------|
| external intercostal m. (a) | inferior border of rib | superior border of rib below | |
| internal intercostal m., interchondral portion (a) | inferior portion of costal cartilages and ribs | costal cartilage and rib below | |
| serratus posterior superior m. (b) | spinous processes of C7 - T2 (or 3) | upper border of 2nd through 5th ribs | |

Accessory muscles of neck, arm, and back (inspiration)



| <u>Name</u> | <u>Origin</u> | <u>Insertion</u> | <u>Action</u> |
|-----------------------------------|--|---|--|
| sternocleidomastoid m. (b) | <u>2 heads:</u> - sternal - clavicular | mastoid process of the temporal bone; occipital bone | |
| trapezius m. (b) | C2-T12 | scapula and clavicle | <i>clinical note: clavicular breathing</i> |

| <u>Name</u> | <u>Origin</u> | <u>Insertion</u> | <u>Action</u> |
|-----------------------------------|-------------------------|------------------|---------------|
| serratus anterior m.(b) | ribs 1-9 | scapula | |
| pectoralis major m.(b) | clavicle and sternum | humerus | |

MUSCLES OF EXPIRATION

Muscles of the Thorax

| <u>Name</u> | <u>Origin</u> | <u>Insertion</u> | <u>Action</u> |
|---|--|--|-------------------------------------|
| internal intercostal m., interosseus portion (b) | superior portion of rib (opposite of interchondral portion) | inferior portion of rib above | <i>clarifying the intercostals:</i> |
| transversus thoracis m.(b) | internal surface of sternum | inner surfaces of costal cartilages 2-6 | |

Abdominal/Back muscles (expiration)

Overview of abdominal/back muscle attachments:

abdominal aponeurosis

linea alba

linea semilunaris

inguinal ligament

lumbodorsal fascia

| <u>Name</u> | <u>Origin</u> | <u>Insertion</u> | <u>Action</u> |
|---|---|--|---------------|
| transversus abdominis m., (b) | inner surface of lower 6 ribs; lumbar fascia | linea alba | |
| external oblique abdominis m.(b) | external portion of lower 7 or 8 ribs | iliac crest, inguinal ligament and abdominal aponeurosis | |
| rectus abdominis m.(b) | pubic bone | xiphoid process; cartilages of ribs 5-7 | |
| latissimus dorsi m.(b) | lower thoracic, lumbar vertebrae; sacrum | upper arm (humerus) | |